THE SCIENCE WORLD
A Monthly e Magazine
ISSN: 2583-2212
July 2022; 2(7), 1120-1130

Popular Article

Chicken Infectious Anaemia: An Emerging Threat to Poultry Industry

Syedah Asma Andrabi[1], Abrar Ul Haq[2], Amarjit Singh[3], Nawab Nashiruddullah[1]

[1]Division of Veterinary Pathology, Faculty of Veterinary Sciences, Sheri Kashmir University of Agricultural Sciences and Technology, Jammu, 181102
[2]Department of Veterinary Medicine, Guru Angad Dev Veterinary and Animal Sciences University, Ludhiana, 141004, Punjab.
[3]Department of Veterinary Pathology, Guru Angad Dev Veterinary and Animal Sciences University, Ludhiana, 141004, Punjab.

Abstract

Chicken Infectious anaemia (CIA) is an economically important immunosuppressive disease of poultry birds with worldwide distribution. It is caused by Chicken anaemia virus (CAV) belonging to genus *Gyrovirus* and family *Circoviridae*. CAV causes severe anaemia, muscular haemorrhages, generalized lymphoid atrophy and immunosuppression in birds less than 3 weeks of age. In birds 6 weeks or older with compromised humoral immune response, the disease takes subclinical form. Yellow fatty bone marrow and thymic atrophy is the most consistent finding in CAV affected birds. Vertical transmission of CAV is more significant but horizontal transmission also occurs and chickens are the only natural host. The disease has no public health significance but recent studies have reported the isolation of the virus and closely related *Gyroviruses* from both healthy and diseased individuals, suggesting that CAV may be potential threat to the public. CIA can be tentatively diagnosed on the basis of clinical signs and gross lesions. However, confirmatory diagnosis can be made by various serological and molecular techniques. There is no specific treatment for the disease but proper disease control and management strategies, breeder vaccination program and measures can help in preventing the outbreaks of CIA.

Keywords: Chicken Infectious Anaemia, Immunosuppression, Gyrovirus, Poultry

1. Introduction

Livestock, including poultry, are the major capital assets and income generating sources of small-scale farmers. The poultry industry in India is the fastest growing components of global agricultural demands because it has a peculiar privilege to improve the living standards of the poor farmers as well as contribute to the sector. It was considered as a backyard venture before the 1960s but now it has transformed into a vibrant agribusiness with an annual turnover of Rs 30000 crores (Mehta and Nambiar, 2006). In spite of rapid growth in India, the poultry industry suffered many setbacks in recent times due to the lack of selection, low genetic potential, rising cost of feed, fluctuating market price of egg and broilers and emergence of new or reemergence of existing diseases, Poultry birds may get infected by various viral, fungal, bacterial, and parasitic diseases which suppresses their overall potential and may cause immunosuppression.

Immunosuppression has a great economic importance in the poultry industry, because affected flocks respond poorly to vaccines, and do not perform as good as non-affected birds. Many viral diseases result in immunosuppression which may be mild to severe depending upon the tissue tropism of virus. It has been known for many years that Infectious Bursal disease virus (IBDV), Chicken infectious Anaemia virus (CIAV), Marek's disease virus (MDV), and Reo virus infection produces direct effect on the immune system of birds. Indeed, combinations of two or more of these viruses can amplify the adverse effects.

Chicken infectious anaemia (CIA) is emerging as a new disease from last three decades which leads to production losses in both percentage of livability and percentage of condemnations (Hagood *et al.*, 2000). CAV is a potent immunosuppressive agent that leads to generalized lymphoid atrophy and transient severe anaemia due to destruction of erythroblastoid cells in bone marrow and immunodeficiency due to depletion of cortical thymocytes resulting in enhanced concurrent infections and vaccination failures. The immunosuppressive effects of CIA on broilers are economically significant and birds may not perform well due to poor feed conversion and reduced weight gain throughout the growing period which may result in increased condemnation rates at slaughter (Mercks Animal Health). The disease usually affects young birds and causes peak mortality within 5-6 days of onset of the acute form of disease which declines after a further 5-6 days (Engstrom and Luthman, 1984, Yuasa *et al*., 1979)

2. Virus (CIAV)

Chicken infectious anaemia (CIA) is caused by the smallest avian virus with size ranging from 23-25 nm belonging to the genus *Gyrovirus* of family *Circoviridae* (Pringle, 1999; Todd *et al.,* 2007, Zhang *et al.,* 2013). The virons are non-enveloped with icosahedral symmetry and a capsid consisting of 60 subunits arranged in 12 pentameric rings. The virus replicates through rolling circle model. The genome organization is negative sense, circular ss-DNA of 1.7 to 2.3 kb having three partially overlapping major open reading frames (ORFs) which encodes for VP1, VP2 and VP3 proteins (Fig 1) **(**Miller *et al.,* 2005, Natesan *et al.,* 2006**)** VP1 acts as a major capsid protein, VP2 as a scaffold protein essential for virus assembly. Both VP1 and VP2 proteins are required to induce protective immunity, the absence of either of VP1 or VP2 fails to induce neutralizing antibodies (Koch *et al*., 1995). A single amino acid at position 394 in VP1 gene is the major genetic determinant of virulance. Presence of histidine instead of glutamine at this position makes the virus less pathogenic (Yamaguchi *et al*., 2001, Andrabi *et al.*, 2021). VP3 (apoptin) causes apoptosis in chicken thymocytes and chicken lymphoblastoid cell lines (Miller *et al*., 2005).

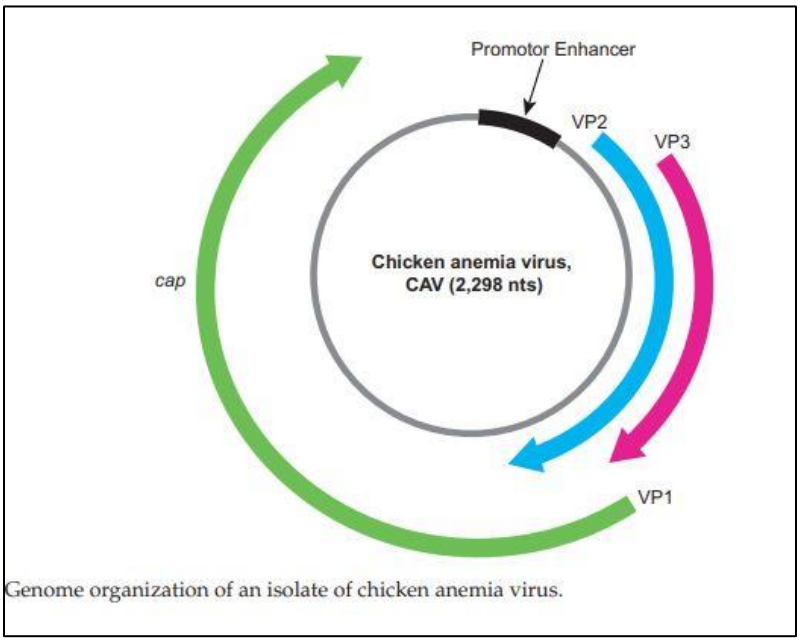

Fig 1: Chicken infectious anemia virus

3. Epidemiology and public health significance

CIA has complex epidemiology as development of clinical disease following infection is dependent on a number of factors that include age of the bird, challenge dose of virus, route of infection, secondary invasion and presence of maternal antibodies (McNulty, 1991, Dhama, 2002;

Schat, 2003a). Another important epidemiological key factor is co-infection with other immunosuopressive viruses such as Marek's disease virus (MDV), Infectious Bursal disease virus (IBDV), Avian Reovirus (ARV) and Adenovirus (Dhama, 2002; Schat, 2003b). CIA has worldwide distribution and has been discovered in almost all poultry producing countries. (Ducatez *et al*., 2008; AboElkhair *et al*., 2014). The disease was first reported in Japan as a new disease in young commercial chicken during investigation of Marek's disease (Yuasa *et al*., 1979). In India CIA was first reported in chickens in Tamil Nadu (Venugopalan *et al.,* 1994). The field outbreaks of CIA were reported from Gujrat and Andhra Pradesh (Praveen *et al*., 2008). A very high serological incidence was reported in commercial poultry farms of northern region in India (Bhatt *et al.,* 2011). Outbreaks of CIA were reported from 2010 to 2016 from Haryana (Brar *et al*., 2019). CIAV outbreaks were reported in young poultry flocks from the Nagpur province of India, between the years 2012–2015 and from Central India as well (Ganar *et al*., 2017; Kamdi *et al*., 2017). CIAV was detected in young commercial poultry flocks from twelve different states of the country including Punjab and adjoining areas (Wani *et al*., 2013, Gowthaman *et al*., 2014; Andrabi *et al.*, 2018; Sreekala *et al*., 2020). Sero-prevalence of the disease has been found in different states including Haryana, Karnataka, Madhya Pradesh, Maharashtra, Tamilnadu and Telangana. (Baksi *et al*., 2016). Recently outbreaks of CIA have been reported from Karnataka and South India (Chandrashekaraiah et al, 2020; Rao *et al.*, 2022).

4. Transmission and pathogenesis

CIA has been reported to be transmitted by both vertical and horizontal route (McNulty 1991; Zhang *et al.,* 2013). Vertical route is important when adult birds become infected because virons can be transferred through embryo during viraemic period prior to the development of neutralizing antibodies. Chickens hatching from such eggs develop anaemia, immunosuppression and secondary bacterial infections. These chicks act as a source of infection during horizontal transmission probably through faeces until neutralizing antibodies develop (Schat 2003a). Chicken infectious anaemia virus (CIAV) enters target cells (Erythroid and lymphoid progenitor cells) by adsorption and penetration, and multiplies in the nucleus by a rolling circle model. The virus causes aplastic anaemia in young chickens by destruction of erythroblastoid cells, and severe depletion of thymocytes leading to thymus atrophy and immunodeficiency (Adair, 2000; Noteborn and Koch 2007) (Fig 2). CAV has specific tropism for lymphocytes leading to lymphocyte depletion. Virus mainly attacks thymic lymphoblasts (CD4+, CD8+ T- cells) and hemocytoblasts (Balamurugan and Kataria, 2006). Virus replicates primarily in haematopoietic precursor cells in bone marrow

and thumic precursor cells in the cortex of thymus where it leads to cytolytic infection (Balamurugan and Kataria, 2006; Rosenberger and Cloud, 1998; Smyth *et al.*, 1993) and cell death by the mechanism of apoptosis which is trigerred by the VP3 protein (Noteborn and Koch, 2007). Later on convalescent stage coincides with antibody development and birds usually recover from depression and anaemia within 4-6 weeks. Body weight gradually returns to the normal but chickens remain stunted. Co-infection with other immunosuppressive viruses such as Mareks disease virus, Infectious Bursal disease virus Avian Reovirus and Adenovirus leads to marked immunosuppression (Dhama, 2002; Todd, 2000). Chicken anemia virus life cycle is illustrated in (Figure 3).

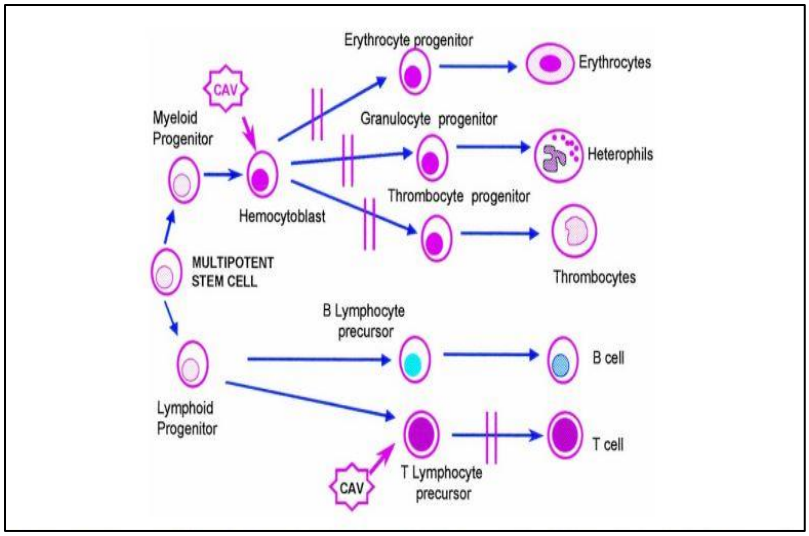

Fig 2: Effect of chicken infectious anemia virus on hemopoiesis and T cell development

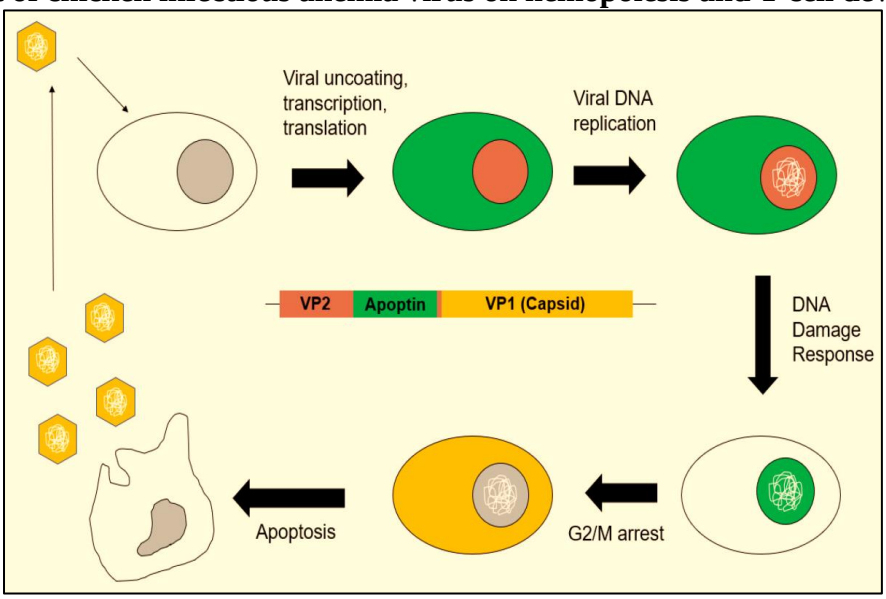

Fig 3: Schematic diagram showing the proposed model of the CAV life cycle
(*Source: Feng et al., 2020; doi: 10.3390/pathogens9040294; Journal Pathogens)*

5. Clinical signs and pathological findings

Under field conditions CIAV infected birds show fewer signs of the disease but co-infection with other infectious agents is more serious. Concurrent infection of CIAV with Avian Reovirus (ARV) causes blue wing disease (BWD), Fowl Adenovirus (FAV) causes aplastic anaemia syndrome, Infectious bursal disease virus (IBDV) causes haemorrhagic anemia syndrome, and with *Clostridium perfringens* and *Staphylococcus aureus* causes gangrenous dermatitis (McNulty 1991, Pope 1991, Dhama *et al.,* 2002; Schat, 2003b**)**

The first signs of the disease appear when the young infected birds are between 7 and 14 days of age (Todd, 2000). Clinically, the disease is characterized by lethargy, ruffled feathers and gangrenous dermatitis under the skin, pale mucous membranes and cutaneous, subcutaneous, and intramuscular hemorrhages (Fig 4, 5, and 6) (Ganar *et al*., 2017; Adedeji *et al*., 2016). Peak mortality occurs within 5-6 days of onset of acute form of disease which declines after a further 5-6 days (Engstrom and Luthman, 1984; Yuasa *et al.,* 1979). Birds show mortality upto 55% and morbidity upto 80% (AboElkhair *et al.,* 2014). Anaemia is a characteristic with decreased hematocrit values and marked thrombocytopaenia in birds as young as 2-4 weeks of age (Kamdi *et al*., 2016).

Although CIAV has tropism for lymphoid organs and noticeable lesions can be found in thymus, bursa, spleen, caecal tonsils and bone marrow (McNulty, 1991), however, lesions can be found in other visceral organs as well (Todd *et al.,* 2001) but these lesions may be largely associated with secondary infections (Miller and Schat, 2004). Most common findings in CIAV infected birds include pale and fatty marrow of femur bone and atrophy of the haematopoietic elements of the bone marrow with marked depletion of erythropoietic and granulopoietic tissue. In much severe cases replacement of haemopoietic cells by lipocytes has been reported (Dhama *et al*., 2002). Depletion of lymphocytes from both cortex and medulla of thymus with indistinct cortical-medullary interface can be manifested in CIAV infected birds (Toro *et al.,* 1997; Andrabi *et al*, 2018). There has been report of moderate to severe lymphoid depletion along with focal necrosis and apoptosis in spleen of CIAV infected birds. Bursa showed mild necrosis of bursal follicles along with lymphoid depletion and proliferation of reticular cells (Kamdi *et al*., 2015). Swollen and mottled liver and spleen with nephrosis in kidneys and highly pale and icteric carcass has been reported in CIA outbreaks (Balamurugan and Kataria, 2006; Gowthaman *et al.,* 2014). Sometimes eosinophilic intranuclear inclusion bodies (EINIB) can be observed in cortical cells of thymus and in bone marrow of infected birds (Goryo *et al*., 1989). However, occasional presence

of intranuclear inclusion bodies in the spleen, proventriculus, lung, kidney, bursa of Fabricius and skin have also been reported (Smyth *et al*., 1993).



Fig 4: Ruffled feather

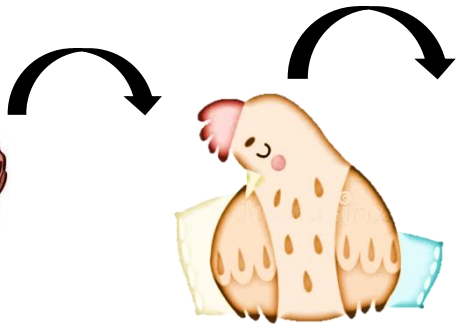

Fig 5: Lethargy

Fig 6: Gangrenous dermatitis
Photo courtesy of Dr. Collett.

6. Diagnosis

Diagnosis of CIA can be made based on clinical signs and pathological lesions in affected birds but this alone is not sufficient to diagnose the condition (Goodwin and Brown, 1992). Various techniques have been described to diagnose CIA. Isolation of the virus in cell culture and embryonated eggs is considered as a gold standard for detection of CIAV but the method is relitavely tedious, cumbersome and expensive (Yuasa *et al*., 1979; McNulty *et al.*, 1989). Other diagnostic techniques like immunohistochemistry, Immunofluorescence and ELISA have also been used but these techniques are usually time consuming and require extensive sample processing. PCR based detection of CIAV is widely used technique because it is relatively inexpensive and fast with high specificity and sensitivity (Saini and Dandapat, 2009). Recently, real-time quantitative PCR-based serum neutralization has been developed for the detection and quantification of CIAV genomes (Van Santen *et al*., 2004).

7. Prevention and Control

CIAV acts synergistically with other infectious agents under field conditions and produces detrimental effects on affected birds. So, the disease is incurable and eradication is unachievable. However, maintaining clean sanitary environment with proper immunization against other bacterial and viral diseases will surely reduce the severity and occurrence of the disease. Genetic selection should be practiced in the field so as to increase the disease resistance of the flocks (Hoerr, 2010). Vertical transmission of the virus can be prevented by the use of vaccine that will

provide acquired immunity to the birds. Various vaccines have been developed against CIAV which include Chicken embryo-propagated Cux-1 isolate live vaccine (104.5TCID50/bird), Cell culture-propagated CAV in drinking water, an effective recombinant subunit vaccine (VP1 and VP2 proteins of CAV) using a baculovirus insect cell culture system (Vielitz *et al*., 1987, Von Bulow and Schat, 1997, Koch *et al*, 1995) but the immunization of birds in India against CIAV is still in its infancy. It is advised to vaccinate the birds at about 13–15 weeks of age, 3–4 weeks prior to the onset of lay to avoid the hazard of spreading vaccine virus through eggs (Vielitz *et al*., 1987; McNulty, 1991). Recently, it has been documented that a single amino acid change at residue 394 of VP1, a major determinant of pathogenicity, can generate a low-pathogenity CAV (Yamaguchi *et al.*, 2001, Andrabi *et al*., 2020). So, these approaches could be good candidates for development of stable, cost effective and safe CAV vaccines, which may be of great help in controlling the disease.

8. Conclusion

CIAV is a potent immunosuppressive agent which along with other infectious agents like Mareks disease virus, Infectious Bursal disease virus, Reovirus, Inclusion body hepatitis virus causes havoc to the poultry industry thus leading to grievous economic losses throughout the world. It leads to chronic debilitation, severe aplastic anaemia, bone marrow suppression, atrophy of lymphoid organs in general and thymic atrophy in particular. Molecular detection of the virus using PCR is highly effective in diagnosing the disease. CIAV is incurable and hence complete eradication is impossible. However, by following the proper biosecurity measures, immunization protocols and management practices, the disease can be well managed. Proper epidemiological surveys need to be conducted to know the strain of the virus circulating in the field so that proper disease control measures and management strategies could be taken accordingly and losses due to subclinical infections could be turned down.

References

AboElkhair M, Abd El-Razak A G, Metwally A E Y. Molecular characterization of chicken anemia virus circulating in chicken flocks in Egypt. Advances in Virology. 2014; 797151

Adair B M Immunopathogenesis of chicken anemia virus infection. Developmental & Comparative Immunology.2000;24(2–3):247-255.

Adedeji A J, Sati N M, Pewan S B, Ogbu K I, Adole J A, Lazarus D D, Ijiwo S J, Okpanachi A, Nwagbo I O, Joannis T M, Abdu P A. Concurrent infections of chicken infectious

anemia and infectious bursal disease in 5 weeks old pullets in Jos, Plateau State, Nigeria. Vet Sci: Res Rev . 2016;2: 60-65.

Andrabi S A, Gupta K, Singh A. Immunohistochemical localization of viral antigens causing immunosuppressive diseases in poultry under field conditions. Indian J Vet Pathol. 2018;42: 191-197.

Andrabi S A, Kimi L, Deka D, Gupta K, Singh A.. Pathology and molecular characterization of field isolates of chicken anaemia virus circulating in commercial poultry in and around Punjab. Indian J Vet Pathol. 2021;45:195-201.

Baksi S, Savaliya B F, Rao N, Khan M. Sero-Prevalence of Chicken Anaemia Virus (CIAV) in layer poultry flocks in different parts of IndiaJournal of Poultry Science and Technology.2016;4(03):39-42.

Balamurugan V, Kataria J M. Economically important non-oncogenic immunosuppressive viral diseases of chicken-current status. Veterinary Research Communications.2006;30(5):541-66.

Bhatt P, Shukla S K, Mahendran M, Dhama K, Chawak M, Kataria J M. Prevalence of chicken infectious anemia virus (CIAV) in commercial poultry flocks of northern India: a serological survey. Transbound Emerg dis. 2011; 58: 458-460.

Brar R, Bhanot V, Mahajan N K, Jindal N, Prakash A. Retrospective studies on epidemiology of chicken infectious anemia in broiler chicken in Haryana. Indian journal of poultry science. 2019; 54: 69-72.

Chandrashekaraiah G B, Karamala S, Doddappaiah N H, Karumuri N K, Kumar, V. Pathology of chicken infectious anemia (CIA) with concurrent infections. Journal of Entomology and Zoology Studies.2020; 8 (2):519-524.

Dhama K. Pathogenicity and immunosuppressive effects of chicken infectious anemia virus (CIAV) in chicks and evaluation of diagnostic tests for its detection. 2002 .Ph.D. Dissertation, Deemed Univ. Indian Veterinary Research Institute, Izatnagar (UP.), India

Engstrom B E and Luthman M. Blue wing disease of chickens: signs, pathology and natural transmission. Avian Pathology.1984; 13: 1-12.

Feng C, Liang Y, Teodoro JG. The Role of Apoptin in Chicken Anemia Virus Replication. *Pathogens*. 2020; 9(4):294.

Ganar K, Shah M, Kamdi B P, Kurkure N V, Kumar S. Molecular characterization of chicken anemia virus outbreaks in Nagpur province, India from 2012 to 2015. Microbial pathogenesis. 2017;102:113-119.

Goryo M, Shibata Y, Suwa T, Umemura T, Itakura C. Outbreak of anemia associated with chicken anemia agent in young chicks. Japanese Journal of Veterinary Science. 1987; 49:867–873.

Gowthaman V, Singh S D, Dhama K, Barathidasan R, Srinivasan P, Mahajan N K, Ramakrishnan M A. Molecular characterization of chicken infectious anemia virus isolated from commercial poultry with respiratory disease complex in India. Adv Anim Vet Sci. 2014; *2*(3):171-176.

Hoerr FJ. Clinical Aspects of Immunosuppression in Poultry. Avian Dieases. 2010; 54: 2-15.

Hu L B, Lucio B, Schat K A. Depletion of CD4+ and CD8+ T lymphocyte sub-populations by CIA-1, a chicken infectious anemia virus. Avian Diseases.1993;37(2):492-500.

Kamdi B P, Kulurkar P M, Bhandarkar A G, Sonkusale P M , Tembhurne P A, Raut S W, Pande R K, Kurkure N V. Study of mortality in young chickens by Chicken infectious

anaemia virus (CIAV) in Nagpur region. Indian Journal of Poultry Science. 2016; 51(3):353-358.

Koch G, Van Roozelaar D J, Verschueren C A, Van der Eb A J, Noteborn M H. Immunogenic and protective properties of chicken anaemia virus proteins expressed by baculovirus. Vaccines.1995; 13:763–770.

McNulty M S. Chicken anaemia agent: A review. Avian Pathology 1991;20(2):187- 203

Miller M M, Jarosinski K W, Schat K A. Positive and negative regulation of chicken anemia virus transcription. Journal of Virology.2005; 79(5): 2859-868.

Natesan S, Kataria J M, Dhama K, Rahul S, Baradhwaj N. 2006. Biological and molecular characterization of chicken anaemia virus isolates of Indian origin. Virus Research. 2006;118(1 2): 78-86.

Noteborn M , Koch G. Chicken anaemia virus infec- tion: Molecular basis of pathogenicity. Avian Pathol. 1995;24:11-31

Pope C R. Chicken anaemia agent. Veterinary Immunology and Immunopathology. 1991;30: 51-65.

Praveen B N, Dhama K, Kataria J M, Dash B B, Singh S D. Detection and isolation of Chicken Infectious Anaemia Virus (CIAV) from field samples of poultry flocks from Gujarat and Andhra Pradesh, India. Indian Journal of Comparative Microbiology, Immunology and Infectious Diseases.2008; 29(1,2):23-26.

Pringle C R. Virus taxonomy at the XIth International Congress of Virology, Sydney, Australia. Archives of Virology.1999;144: 2065-70.

Rosenberger J K , Cloud S S. Chicken anemia virus. Poultry Sciences 1998;77:1190-92.

Saini N S, Dandapat A. Diagnosis and Molecular Characterization of Chicken Anaemia Virus. Vet World. 2009;2:156- 160.

Schat K A. Chicken infectious anemia. In*:* Diseases of Poultry, 11th ed. (Editors) Saif YM, Barnes HJ, Glisson JR, Fadly AM, Mcdougald LR and Swayne DE. Iowa State University Press. Ames, USA.2003a:182-202.

Schat K A. Marek's disease, Chicken infectious anemia and Immunosuppression: a nasty combination,the poultry research foundation / the world's poultry science association in proceedings of australian poultry science symposium. Annual Australian poultry science symposium 2003b;15:51-57.

Smyth J A, Moffett D A, McNulty M S, Todd O , Mackie D P. A sequential histopathologic and immunocytochemical study of chicken anemia virus infection at one day of age. Avian Diseases.1993; 37: 324-38.

Sreekala S M, Gurpreet K, Dwivedi P N. Detection and molecular characterization of chicken infectious anaemia virus in young chicks in Punjab region of north-western India. Brazilian Journal of Microbiology. 2020;51(2):805-813.

Todd D, Scott A N J, Fringuelli E, Shivraprasad H L, Gavier-Widen D, Smyth J A. Molecular characterization of novel circoviruses from finch and gull. Avian Pathology. 2007;36(1):75-81.

Todd D. Circoviruses: Immunosuppressive threats to avian species: A review. Avian Pathology. 2000;29(5): 373-94

Toro H, Ramirez A M, Larenas J. Pathogenicity of chicken anaemia virus (isolate 10343) for young and older chickens. Avian Pathology. 1997; 26(3): 485-99.

Van Santen V L, Kaltenboeck B, Joiner K S, Macklin K S, Norton R A. Real-time quantitative PCR based serum neutralization test for detection and titration of neutralizing

antibodies to chicken anemia virus. Journal of Virological Methods. 2004;115:123–135.

Venugopalan A T, Elankumaran S, Raj G D, Manohar B M, Thangavelu A, Ravikumar G, Koteeswaran A, Raj A S. Isolation of chicken anaemia virus in Tamil Nadu. Indian Veterinary Journal.1994;71(4): 411-12.

Vielitz, E, Von Bulow V, Landgraf H, Conrad C. Anemia in broilers: development of a vaccine for parent stock. Journal of Veterinary Medicine.1987; B34:553–557.

Von Bulow V, Schat K A. Infectious anemia. In: B.W. Calnek, H.J. Barnes, C.W. Beard, W.M. Reid and H.W. Yoder, Jr (eds), Diseases of Poultry, 10th edn, (Iowa State University Press, Ames, IA).1997; 690–699.

Xu Y E, Uu Z G. Influence of chicken infectious anaemia virus infection on the immune system in chicks. Chinese Journal of Veterinary Sciences.1995; 15: 33- 37.

Yamaguchi S, Imada T, Kaji N, Mase M, Tsukamoto K, Tani- mura N, Yuasa N. Identifi cation of a genetic deter- minant of pathogenicity in chicken anaemia virus. J Gen Virol. 2001; 82:1233–1238.

Yuasa, N, Taniguchi T, Yoshida I. Isolation and some characteristics of an agent inducing anemia in chicks. Avian Diseases.1979;23:366-385.

Zhang X, Liu Y, Wu B, Sun B, Chen F, Ji J, Ma J, Xie Q. Phylogenetic and molecular characterization of chicken anemia virus in southern China from 2011 to 2012. Scientific Reports.2013; 3*:* 3519