THE SCIENCE WORLD
A Monthly e Magazine

ÍSSN: 2583-2212
July 2022; 2(7), 1190-1194

Review Article

Lumpy Skin Disease, an Emerging Viral Disease

Rashmi, Mahendra Kumar Meena
Department of Veterinary Pathology
Rajasthan University of Veterinary and Animal Sciences, Bikaner

Abstract

Lumpy skin disease is an emerging bovine viral disease, which is endemic in most African countries and some Middle East ones, and the elevated risk of the spread of disease into the rest of Asia and Europe should be considered. The recent rapid spread of disease in currently disease-free countries indicates the importance of understanding the limitations and routes of distribution. The causative agent, Capri pox virus, can also induce sheep pox and goat pox. The distribution of Capri pox viruses seems to be expanding due to limited access to effective vaccines and poverty within farming communities. The information on the various aspects of the disease such as its clinicopathology, transmission, diagnosis, prevention and control measures, and the potential role of wildlife in the further spread of disease.

Keywords: Capri pox, lumpy skin disease.

Introduction

Lumpy skin disease (LSD), a major threat to stockbreeding, can cause acute or subacute disease in cattle and water buffalo (Givens, 2018; Tuppurainen, Venter, et al., 2017). All ages and breeds of cattle are affected, but especially the young and cattle in the peak of lactation. The reason why the World Organization for Animal Health (OIE) has placed this transboundary disease on the notifiable disease list is due to its significant economic losses and the potential for rapid spread. Lumpy skin disease virus (LSDV) is a double-stranded DNA enclosed in a lipid envelope and belongs to genus Capri poxvirus, which is genetically related to the sheep pox (SPPV) and goat pox (GTPV) viruses (Givens, 2018). The capsid or nucleocapsid of the virus is brick or oval shaped containing the genome and lateral bodies.

Transmission

Lumpy skin disease can affect cattle, water buffalo and wild ruminants. LSDV can remain viable for long periods in the environment at ambient temperatures, especially in dried scabs. The main sources of infection are considered to be skin lesions as the virus persists in the lesions or scabs for long periods.

The LSDV is transmitted through contaminated feed, water and direct transmission in the later stages of the disease via saliva, nasal secretions and semen (Annandale et al., 2014; Tuppurainen, Venter, et al., 2017). As most LSD outbreaks have occurred in the summer when arthropods are most active, it may indicate the involvement of various vector species, especially blood-feeding insects, in virus spread (Sprygin et al., 2018).

Pathogenesis

LSDV infection, virus replication, viremia, fever, cutaneous localization of the virus and development of nodules occur (Constable et al., 2017). Experimentally, after intradermal inoculation of the virus, the following events were reported: • 4 to 7 days post-infection (DPI): localized swelling as 1–3 cm nodules or plaques at the site of inoculation • 6 to 18 DPI: viremia and shedding of the virus via oral and nasal discharge • 7 to 19 DPI: regional lymphadenopathy and development of generalized skin nodules • 42 days after fever: presence of virus in semen. Intracellular replication of the virus in fibroblasts, macrophages, pericytes and endothelial cells leads to vasculitis and lymphangitis in affected tissues.

Clinicopathology

The clinical features of the disease include fever, inappetence, nasal discharge, salivation and lachrymation, enlarged lymph nodes, a considerable reduction in milk production, loss of body weight and sometimes death (Tasioudi et al., 2016). Furthermore, the disease is characterized by firm, slightly raised, circumscribed skin nodules that are 2–7 cm in diameter and typically appear on the neck, legs, tail and back, (Fig.1) shortly after the beginning of fever (Beard, 2016; Sevik & Dogan, 2017). With necropsy, lung oedema and congestion, nodules throughout the lungs and gastrointestinal tract were often observed (Zeynalova et al., 2016). Tissues such as the muzzle, nasal cavity, larynx, trachea, inside of the lips, dental pad, gingiva, abomasum, udder, teats, uterus, vagina and testes might be affected. The complications of severe disease were reported as keratitis, dysentery, lameness, pneumonia, mastitis and myiasis (Tuppurainen et al. 2017). The histopathological examination of skin nodules may reveal pathognomonic eosinophilic intracytoplasmic inclusion bodies in the keratinocytes, macrophages, endothelial cells are associated with the ballooning degeneration of spinosum cells. Infiltration of the superficial dermal tissue of affected areas by inflammatory cells such as macrophages, lymphocytes and eosinophils is seen. In addition, widespread vasculitis and severe coagulative necrosis and hydrophic degeneration in subcutaneous muscles may be observed in some cases (Constable et al. 2017)

(Fig.2).

Figure 1: Gross photograph showing nodular lesions on skin

Figure 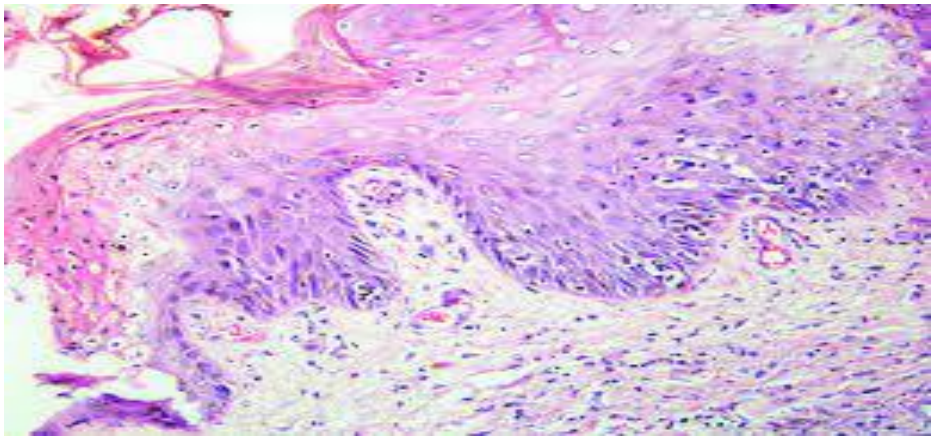 **2:**

Photomicrograph showing proliferation of epidermal cells with hydrophic degeneration of cells H&E (20x)

Diagnosis

Despite a primary clinical diagnosis of LSD, the diagnosis is confirmed by using conventional PCR for differentiating virulent LSDV from the vaccine strain, Restriction Fragment Length Polymorphism (RFLP) has also been used. Among serological techniques, the virus neutralization test, which is slow and costly with a high specificity and low sensitivity, is the only currently valid test (Beard, 2016).

Prevention and Control

The distribution of capripox viruses seems to be expanding due to limited access to effective vaccines and poverty in farming communities in endemic regions, as well as the increased legal and illegal trading of live animals, besides global climate change s. Vaccination is the only effective method to control the disease in endemic areas along with movement restrictions and the removal of affected animals (Sevik & Dogan, 2017). The culling of affected animals, movement

restrictions and compulsory and consistent vaccination have been recommended as control strategies. However, regarding the role of arthropod vectors, elimination of the disease is likely to be difficult and any delays in the removal of infected animals increase the risk of LSD transmission (Tuppurainen, Venter, et al., 2017). Educating veterinarians and livestock workers would enable them to perform timely diagnoses of clinical cases, helping to slow the spread of disease (Beard, 2016). Furthermore, the rapid confirmation of a clinical diagnosis is essential so that eradication measures, such as quarantine, slaughter-out of affected and in-contact animals, proper disposal of carcasses, cleaning and disinfection of the premises, and insect control can be implemented as soon as possible during the eruption (Constable et al., 2017). Moreover, rigorous import restrictions on livestock, carcasses, hides and semen from endemic areas must be in place in disease-free areas (Sevik & Dogan, 2017). The commercially accessible vaccines against LSD are live attenuated vaccines. Although cutaneous lesions have developed in some vaccinated animals after exposure to the virus, there were a greater amount of clinical cases in unvaccinated flock compared with vaccinated flock .Live vaccines produce a strong and long-lasting immune response, and are efficient in the control of disease spread. However, live vaccines can cause local inflammation and a mild disease with skin lesions. Although inactivated vaccines are costly and need several administrations, they are safe and it is possible to combine them with other antigens to make polyvalent vaccines that could be used in disease-free countries. Moreover, inactivated vaccines could be applied in the final stage of disease eradication as a part of the strategy that uses live vaccines first (Hamdi et al., 2020).

Conclusions

The recent spread of the disease into disease-free areas indicates its epidemiological and economic significance. Considering the extensive boundaries of Middle East countries, animal movements among these countries should be attentively controlled by veterinary authorities. Furthermore, paying close attention to the different aspects of the disease, such as transmission and epidemiology, and the implementation of effective preventive measures such as vaccination, could result in better disease control. Therefore, accurate and timely diagnosis in endemic areas, vaccination with the homologous strain of the LSDV, vector control, animal movement restriction and LSDV testing of bulls used for breeding are highly recommended as tools to control further spread.

References

Annandale, C. H., Holm, D. E., Ebersohn, K., & Venter, E. H. (2014). Seminal transmission of lumpy skin disease virus in heifers. Transboundary and Emerging Diseases, 61, 443–448.

Beard, P. M. (2016). Lumpy skin disease: A direct threat to Europe. Veterinary Record, 178(22), 557–558.

Constable, P. D., Hinchcliff, K. W., Done, S. H., & Grundberg, W. (2017). Veterinary medicine: A textbook of the diseases of cattle, horses, sheep, pigs, and goats (11th ed., p. 1591). Elsevier

Givens, M. D. (2018). Review: Risks of disease transmission through semen in cattle. Animal, 12(S1), s165–s171.

Hamdi, J., Boumart, Z., Daouam, S., El Arkam, A., Bamouh, Z., Jazouli, M., Tadlaoui, K. O., Fihri, O. F., Gavrilov, B., & El Harrak, M. (2020). Development and evaluation of an inactivated lumpy skin disease vaccine for cattle. Veterinary Microbiology, 245, 108689.

Sevik, M., & Dogan, M. (2017). Epidemiological and molecular studies on lumpy skin disease outbreaks in Turkey during 2014–2015. Transboundary and Emerging Diseases, 64(4), 1268–1279.

Sprygin, A., Babin, Y., Pestova, Y., Kononova, S., Wallace, D. B., Van Schalkwyk, A., Byadovskaya, O., Diev, V., Lozovoy, D., & Kononov, A. (2018). Analysis and insights into recombination signals in lumpy skin disease virus recovered in the field. PLoS One, 13(12), e0207480.

Tasioudi, K. E., Antoniou, S. E., Iliadou, P., Sachpatzidis, A., Plevraki, E., Agianniotaki, E. I., Fouki, C., Mangana-Vougiouka, O., Chondrokouki, E., & Dile, C. (2016). Emergence of lumpy skin disease in Greece, 2015. Transboundary and Emerging Diseases, 63, 260–265.

Tuppurainen, E. S., Venter, E. H., Shisler, J. L., Gari, G., Mekonnen, G. A., Juleff, N., Lyons, N. A., De Clercq, K., Upton, C., Bowden, T. R., Babiuk, S., & Babiuk, L. A. (2017). Review: Capripoxvirus diseases: Current status and opportunities for control. Transboundary and Emerging Diseases, 64(3), 729–745.

Zeynalova, S., Asadov, K., Guliyev, F., Vatani, M., & Aliyev, V. (2016). Epizootology and molecular diagnosis of lumpy skin disease among livestock in Azerbaijan. Frontiers in Microbiology, 7, 1022.